



Case Presentation

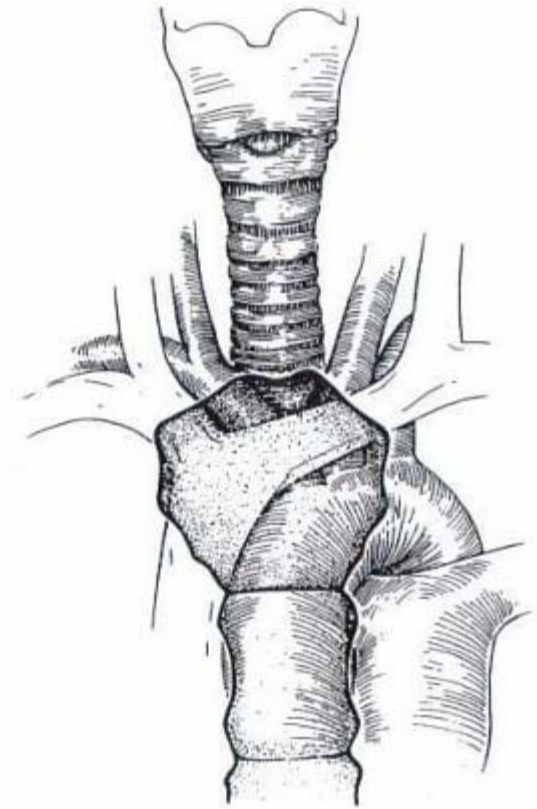
Valery Dronsky, MD
Lutheran Medical Center
Friday, April 22, 2005



Management of Tracheoinnominate Artery Fistula

Anatomy

- The trachea is about 11.8 cm long
- There are 18 to 22 cartilaginous rings
- Each ring is about 0.5 cm wide
- Internal diameter in adults is 2.3 cm laterally and 1.8 cm anteroposteriorly
- The cricoid is the only complete cartilaginous ring in the trachea
- The innominate artery crosses over the anterior trachea in a left anterolateral to high right anterolateral direction



Tracheoinnominate Artery Fistula

- Tracheoinnominate Artery Fistula- erosion into innominate artery by tracheostomy tube
- Tracheoinnominate fistula, although more rare since the advent of low-pressure tracheostomy tubes, remains a highly lethal complication of tracheostomy
- The mortality rate approaches 100%, even when surgical intervention is undertaken

C.D. Wright, Management of tracheoinnominate artery fistula. *Chest Surg Clin N Am* **6** (1996), pp. 865–873.

Tracheoinnominate Artery Fistula

Historical Aspects

- 1879- Korte reported a fatal TIF in 5-year old child with diphtheria after tracheostomy
- 1924- Schlaepter reviewed 115 cases of fatal hemorrhage after tracheostomy and documented that the innominate artery was involved in most cases
- 1964- Silen reported the first short-term survivor
- 1968- Reich reported the first long-term survivor of TIF

C.D. Wright, Management of tracheoinnominate artery fistula. *Chest Surg Clin N Am* **6** (1996), pp. 865–873.

Tracheoinnominate Artery Fistula Incidence



- The incidence of TIF in tracheostomies has ranged from 0% to 1% and averages 0.3%
- The overall incidence of postoperative hemorrhage after tracheostomy is 3%
- 10% of post-tracheostomy hemorrhage is due to TIF
- The incidence is higher in patients with head injuries, presumably owing to the relentless movement of these patients

¹ Dyer RK, Fisher SR: Tracheal-innominate and tracheal-esophageal fistula. Complication in Thoracic Surgery. St. Louis, Mosby-Year Book, 1992, p 294

² Mehalic TF, Farhat SM: Tracheoarterial fistula: A complication of tracheostomy in patients with brain stem injury. J Trauma 12:140, 1972

Tracheoinnominate Artery Fistula Incidence



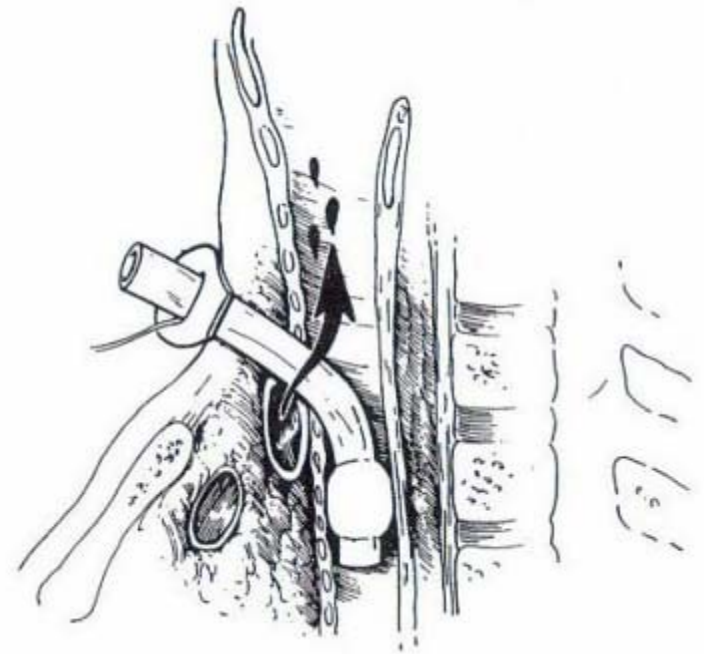
- TIF has been reported to occur as early as 2 days and as late as many months following tracheostomy
- The peak incidence of TIF is between the first and second week after tracheostomy
- 75% of TIF present within 3-4 weeks after tracheostomy placement

¹ Gelman JJ, Aro M, Weiss SM: Tracheo-innominate artery fistula. J Am Coll Surg 179:626, 1994

² Jones JW, Reynolds M, Hewitt RL: Tracheo-innominate artery erosion: Successful surgical management of a devastating complication. Ann Surg 184:194,1976

Tracheoinnominate Artery Fistula Pathogenesis

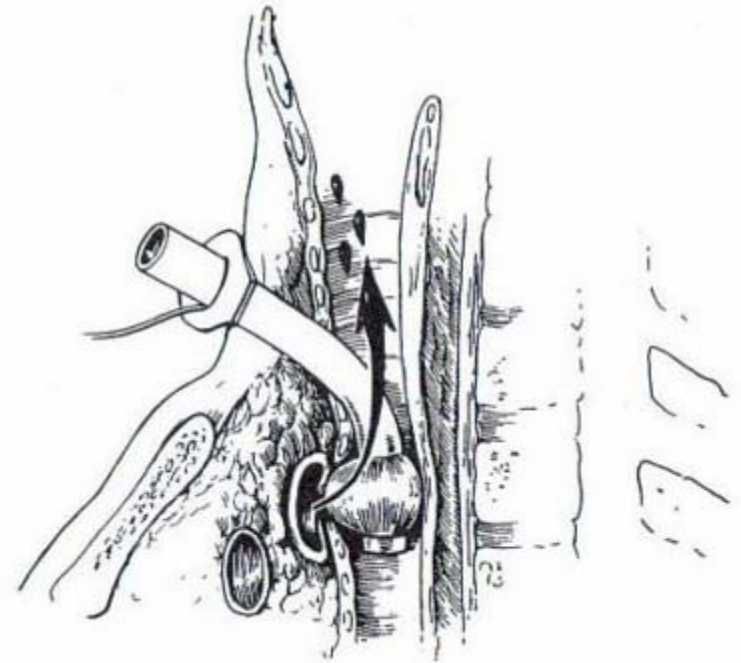
- The mechanism of injury in TIF after tracheostomy is pressure necrosis from the elbow, cuff, or tip of the tracheostomy tube
- The location of the fistula is at the cannula tip or cuff in two thirds of the reported patients
- The close anatomical juxtaposition of the trachea and innominate artery is the reason for TIF after tracheostomy



Jones JW, Reynolds M, Hewitt RL: Tracheo-innominate artery erosion: Successful surgical management of a devastating complication. *Ann Surg* 184:194,1976

Tracheoinnominate Artery Fistula Pathogenesis


- The mechanism of injury in TIF after tracheostomy is pressure necrosis from the elbow, cuff, or tip of the tracheostomy tube
- The location of the fistula is at the cannula tip or cuff in two thirds of the reported patients
- The close anatomical juxtaposition of the trachea and innominate artery is the reason for TIF after tracheostomy



Jones JW, Reynolds M, Hewitt RL: Tracheo-innominate artery erosion: Successful surgical management of a devastating complication. Ann Surg 184:194,1976

Tracheoinnominate Artery Fistula Pathogenesis

- The mechanism of injury in TIF after tracheostomy is pressure necrosis from the elbow, cuff, or tip of the tracheostomy tube
- The location of the fistula is at the cannula tip or cuff in two thirds of the reported patients
- The close anatomical juxtaposition of the trachea and innominate artery is the reason for TIF after tracheostomy



Jones JW, Reynolds M, Hewitt RL: Tracheo-innominate artery erosion: Successful surgical management of a devastating complication. *Ann Surg* 184:194,1976

Tracheoinnominate Artery Fistula Pathogenesis



- Anatomical variations:

- The innominate artery normally covers the trachea at the ninth tracheal ring, with a range from the sixth to the thirteenth ring
- The innominate artery present in normal fashion only 74% of whites and 53% of blacks
- The most common variation- the left common carotid artery originating from the base of the innominate artery, 20% whites and 38% blacks

¹ Oshinsky AE, Rubin JS, Gwozdz CS: The anatomical basis for post-tracheostomy innominate artery rupture. Laryngoscope 98:1061, 1988

² McDonald JJ, Anson BJ: Variation in the origin of arteries derived from the aortic arch. Anat Rec 62:139, 1935

Tracheoinnominate Artery Fistula Pathogenesis

- The innominate artery is the most common artery involved in massive hemorrhage after tracheostomy
- Although other vessels involved:
 - common carotid artery
 - inferior thyroid artery
 - thyroid ima artery
 - innominate vein
 - aortic arch
- Other causes: stomal and tracheal granulation tissue, tracheitis

Tracheoinnominate Artery Fistula Pathogenesis



- Clinical characteristics contributing to TIF:
 - Long-term ventilation
 - Excessive movement of the tracheostomy
 - High airway pressures requiring correspondingly high cuff pressures to prevent air leakage
 - Sepsis
 - Frequent hypotension
 - Radiation therapy
 - Steroid therapy
 - Malnutrition
 - Infection
 - Diabetes mellitus

Cooper JD, Grillo HC: The evolution of tracheal injury due to ventilatory assistance through cuffed tubes: A pathologic study. Ann Surg 169:334, 1969

Tracheoinnominate Artery Fistula Pathogenesis

- Technical characteristics contributing to TIF:
 - Malfitting and poorly positioning tracheostomy tube
 - 90 degree tubes
 - Rigid tubes
 - Improperly placed low tracheostomy below the fourth ring
 - High-lying innominate artery, especially in young patients
 - Peculiar neck anatomy resulting in excessive anterior pressure

Jones JW, Reynolds M, Hewitt RL: Tracheo-innominate artery erosion: Successful surgical management of a devastating complication. Ann Surg 184:194,1976

Tracheoinnominate Artery Fistula Pathogenesis

- TIF after upper airway reconstruction:
 - After tracheal resection and reconstruction:
 - due to necrosis and/or separation of suture line, excessive tension, prior radiation, DM, steroids
 - After mediastinal tracheostomy:
 - due to excessive tension
 - Also has been reported after placement of expandable metallic stent for tracheal stenosis

¹ Grillo HC, Mathisen DJ: Cervical exenteration. Ann Thorac Surg 49:401, 1990

² Maynar M, Lopez L, Gorriz E: Massive brachiocephalic artery bleeding due to a Gianturco tracheal stent. J Vasc Interv Radiol 4:289, 1993

Tracheoinnominate Artery Fistula Management Strategy



- The currently advocated management strategy in dealing with TIF:
 - Prompt diagnosis
 - Emergency management
 - Definitive operative repair

Tracheoinnominate Artery Fistula

Diagnosis



- A high index of suspicion is necessary
 - Early diagnosis is the key to successful management
 - The 50% patient usually has had one or more previous sentinel hemorrhages. Investigation of these sentinel hemorrhage episodes is imperative
 - Bleeding that occurs 48 hours or later after tracheostomy should be presumed to be TIF until proven otherwise

Jones JW, Reynolds M, Hewitt RL: Tracheo-innominate artery erosion: Successful surgical management of a devastating complication. Ann Surg 184:194,1976

Tracheoinnominate Artery Fistula

Diagnosis



- Management of possible sentinel bleeding:
 - Rigid bronchoscopy with a 0° telescope to examine the stoma and anterior wall with tracheostomy tube removed
 - Performed in OR with equipment available for prompt surgical intervention
 - The rigid bronchoscope can be used to compress the innominate artery against the sternum to control hemorrhage
- Pulsation of the tracheostomy tube has been described as warning sign, but has been present in a small number of patients
- Massive bleeding presents no problem in Diagnosis

¹ C.D. Wright, Management of tracheoinnominate artery fistula. *Chest Surg Clin N Am* 6 (1996), pp. 865–873.

² Cooper JD: Trachea-innominate artery fistula: Successful management of three consecutive patients. *Ann Thorac Surg* 24:439,1977

Tracheoinnominate Artery Fistula

Diagnosis

- **Angiography:**

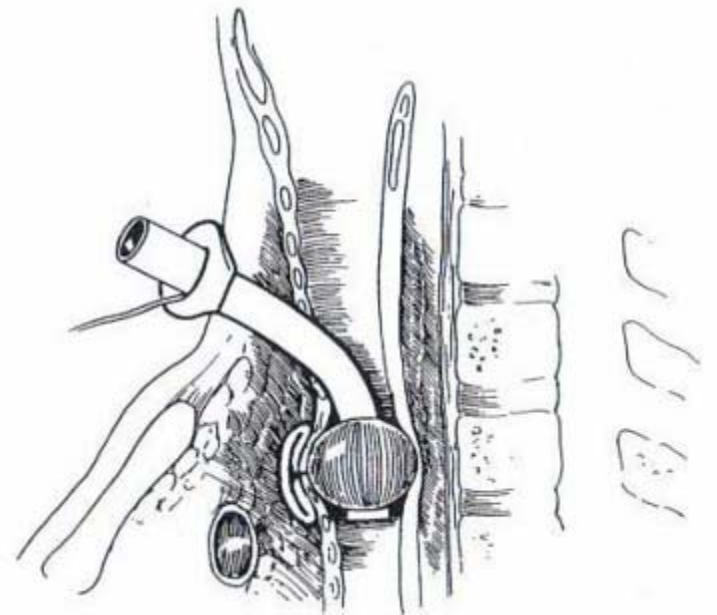
- Useful in patients with minor bleeding who have a negative bronchoscopic examination or false negative
- Both views should be obtained: anterior and lateral
- Not possible in massive bleeding and has accuracy only about 20%

¹ C.D. Wright, Management of tracheoinnominate artery fistula. *Chest Surg Clin N Am* **6** (1996), pp. 865–873.

² J.W. Jones, M. Reynolds, R.L. Hewitt and T. Drapanas, Tracheo-innominate artery erosion: successful surgical management of a devastating complication. *Ann Surg* **184** (1976), pp. 194–204.

Tracheoinnominate Artery Fistula Emergency Management

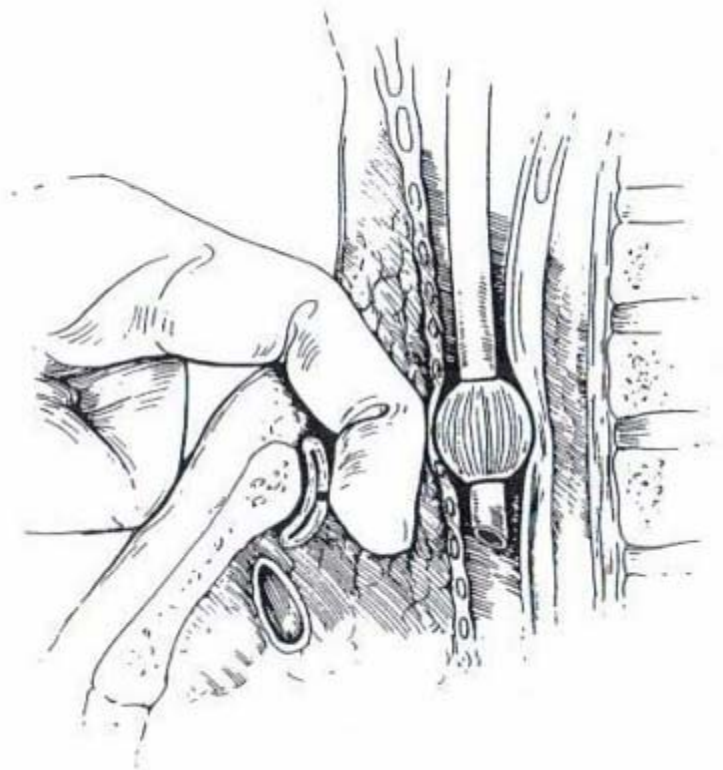
- Massive hemorrhage from the trachea = TIF
- Survival possible only if bleeding can be controlled at the bedside prior to definitive control in the OR
 - First maneuver should be overinflation of the cuff of the tracheostomy
 - Successful in 85% of cases
- If bleeding persists:
 - The tube should be slowly withdrawn with pressure directed against the anterior tracheal wall



J.W. Jones, M. Reynolds, R.L. Hewitt and T. Drapanas, Tracheo-innominate artery erosion: successful surgical management of a devastating complication. *Ann Surg* **184** (1976), pp. 194–204.

Tracheoinnominate Artery Fistula Emergency Management

- If overinflation of the cuff does not control the hemorrhage:
 - An oral endotracheal tube should be placed
 - The tracheostomy tube is removed
 - Digital compression of the innominate artery is applied
 - Entering the pretracheal fascial plane through the tracheostomy wound
 - Bluntly dissect innominate artery off the trachea with index finger
 - Compressed against the sternum
 - Successful in about 90% of the cases



¹ J.W. Jones, M. Reynolds, R.L. Hewitt and T. Drapanas, Tracheo-innominate artery erosion: successful surgical management of a devastating complication. *Ann Surg* **184** (1976), pp. 194–204.

² Utley JR, Singer MM, Roe BB: Definitive management of innominate artery hemorrhage complicating tracheostomy. *JAMA* 220:577, 1972

Tracheoinnominate Artery Fistula Emergency Management

- Preoperative management:
 - Clearance of the distal airway
 - Volume resuscitation
 - Blood transfusion
 - Occlusion of the innominate artery must be maintained during transport to the operating room and until control of the artery is achieved

¹ J.W. Jones, M. Reynolds, R.L. Hewitt and T. Drapanas, Tracheo-innominate artery erosion: successful surgical management of a devastating complication. *Ann Surg* **184** (1976), pp. 194–204.

² Utley JR, Singer MM, Roe BB: Definitive management of innominate artery hemorrhage complicating tracheostomy. *JAMA* 220:577, 1972

Tracheoinnominate Artery Fistula

Operative management

- The optimum surgical correction for TIF, however, remains controversial
- Two basic strategies:
 - Approaches that maintain flow through the innominate artery
 - Direct repair of the defect
 - Interposition grafting
 - Approaches that interrupt flow through the innominate artery
 - Simple ligation
 - Resection of the innominate artery with bypass, while attempting to preserve the right carotid–right subclavian junction

Tracheoinnominate Artery Fistula

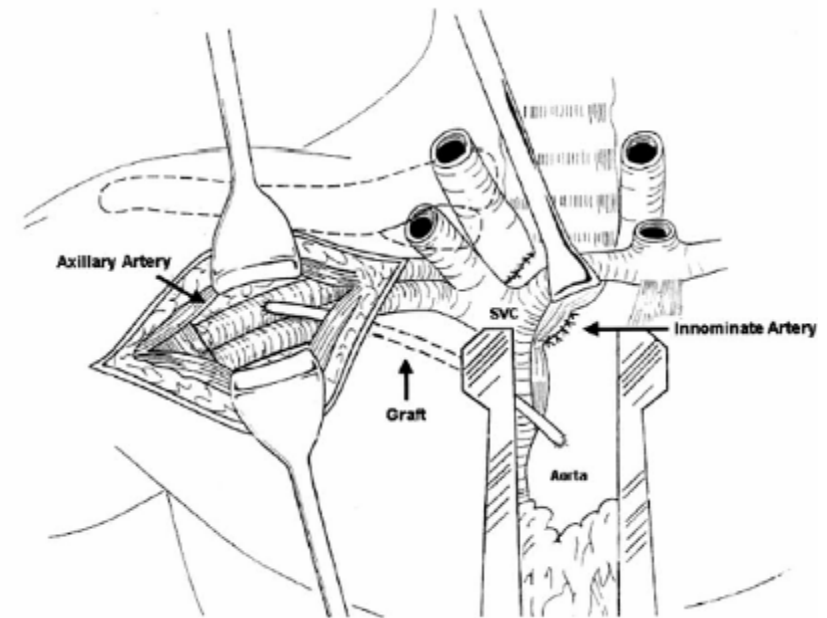
Operative management

- Maintenance of innominate flow:
 - Direct repair
 - Construction of an "in situ" bypass conduit
- The rebleeding episodes in these patients are predictable
 - By definition, the area of a TIF is infected
 - Suture repair of an infected artery or graft placement in an infected field is doomed to failure
 - Recurrent bleeding 60% and death 86% versus 7% and 29% with simple division

Tracheoinnominate Artery Fistula

Operative management

- Most authors currently advocate interruption of flow
 - Gelman, et al¹: Reviewed 71 survivors of TIF from 1962 to 1994
 - Of the 71 initial survivors, only 40 survived "long-term" (>2 months)
 - Maintenance of flow resulted in 15.8% "long-term" survival, whereas interruption of flow resulted in 71.2% "long-term" survival
 - Yang, et al²:
 - Reviewed 24 survivors of TIF from 1975 to 1984
 - Comparable results



¹ Gelman JJ, Aro M, Weiss SM. Tracheo-innominate artery fistula. J Am Coll Surg 1994;179:626–34.

² Yang FY, Criado E, Schwartz JA, Keagy BA, Wilcox BR. Trachea-innominate artery fistula: retrospective comparison of treatment methods. South Med J 1988;81:701–6.

Tracheoinnominate Artery Fistula

Operative management

- Majority of authors believe that ligation of the innominate artery is the treatment of choice
 - Decreased rebleeding rates
 - Decreased mortality
- Bypass or simple ligation?
 - No reports of significant neurologic sequelae or vascular complications associated with innominate artery ligation
 - Restoration of flow may not be crucial
 - However, reported survivors with intact neurologic function have had an average age of 24.5
 - Ligation may only be safe in patients without atherosclerosis

Tracheoinnominate Artery Fistula

Operative management

- Full median sternotomy has been traditionally the most common approach
- One report noted 40% incidence of sternal wound complications due to contamination by tracheal secretion following TIF repair
- An upper partial sternotomy that is T-ed off into the right third interspace is preferred

1 C.D. Wright, Management of tracheoinnominate artery fistula. *Chest Surg Clin N Am* 6 (1996), pp. 865–873.

2 Cooper JD: Trachea-innominate artery fistula: Successful management of three consecutive patients. *Ann Thorac Surg* 24:439,1977

Tracheoinnominate Artery Fistula

Operative management

- Innominate artery is exposed by division of the thymus and superior retraction of innominate vein
- Proximal and distal control
- Inspection of proximal innominate artery for anomaly
- An anomalous left common carotid is preserved by division of the artery distal to it

C.D. Wright, Management of tracheoinnominate artery fistula. *Chest Surg Clin N Am* 6 (1996), pp. 865–873.

Tracheoinnominate Artery Fistula Results



- Currently approximately 70 reported survivors after an operation for TIF
- Only 40 survived more than two months
- Approximately 25% of patients with TIF who are brought to the OR survive

C.D. Wright, Management of tracheoinnominate artery fistula. *Chest Surg Clin N Am* **6** (1996), pp. 865–873.

J.J. Gelman, M. Aro and S.M. Weiss, Tracheo-innominate artery fistula. *J Am Coll Surg* **179** (1994), pp. 626–634.

Tracheoinnominate Artery Fistula Prevention

- Prevention the best treatment
- Tracheostomy should be reserved for patients requiring ventilation longer than two weeks
- Should be performed in controlled setting with a secure airway by an experienced surgeon
- Excessive hyperextension of the neck should be avoided
- The anterior trachea should always be fully exposed by division of the thyroid isthmus so that tracheal rings may be counted properly
- Accurate placement of the stoma in the second and third ring
- Tracheal rings should always be counted from the cricoid

Tracheoinnominate Artery Fistula Prevention

- Pliable noncreative tracheostomy tubs preferable
- Cuff pressures should be monitored frequently and should not exceed 20 mm Hg
- Tight closure of the tracheostomy skin incision should be avoided to reduce the risk of wound sepsis
- Prompt treatment of peristomal sepsis
- Ventilator induced tracheostomy movement should be minimized with long flexible connecting tubing
- If there any doubt about the proper position of tube flexible bronchoscopy should be performed

Tracheoinnominate Artery Fistula

- Tracheoinnominate fistula is a devastating complication of tracheostomy
- Although the advent of low-pressure cuffs has made this a rare complication, mortality associated with TIF remains high
- The outcome following TIF is largely dependent upon its timely diagnosis and prompt management with most authors advocating simple ligation or resection due to high reported rates of rebleeding associated with vascular reconstruction